

# Active Infection: Evidence of Persistence in Chronic Lyme Disease

## IDSA Guidelines

### Contested Recommendation

ξ “To date, there is no convincing biologic evidence for the existence of symptomatic chronic *B. burgdorferi* infection among patients after receipt of recommended treatment regimens for Lyme disease. Antibiotic therapy has not proven to be useful and is not recommended for patients with chronic (6 months) subjective symptoms after administration of recommended treatment regimens for Lyme disease (E-I).”

pp. 1120-21

Steven Phillips, MD

IDSA Guidelines Review Hearing 7/30/09

# Biologic Plausibility: Data NOT Cited by IDSA & Data Cited Inconsistently\*

ξ “the lack of antibiotic resistance in this genus”

ξ IDSA Guidelines

ξ ***Bb* has shown antimicrobial resistance against many of the major antibiotic classes**

ξ \* Terekhova D, Sartakova ML, [Wormser GP](#), Schwartz I, Cabello FC. Erythromycin resistance in *Borrelia burgdorferi*. *Antimicrob Agents Chemother*. 2002 Nov;46(11):3637-40.

ξ Santino I, Scazzocchio F, Ciceroni L, Ciarrocchi S, Sessa R, Del Piano M. In vitro susceptibility of isolates of *Borrelia burgdorferi* s.l. to antimicrobial agents. *Int J Immunopathol Pharmacol*. 2006 Jul-Sep;19(3):545-9.

ξ Jackson CR, Boylan JA, Frye JG, Gherardini FC. Evidence of a conjugal erythromycin resistance element in the Lyme disease spirochete *Borrelia burgdorferi*. *Int J Antimicrob Agents*. 2007 Dec;30(6):496-504.

ξ Galbraith KM, Ng AC, Eggers BJ, Kuchel CR, Eggers CH, Samuels DS. ParC mutations in fluoroquinolone-resistant *Borrelia burgdorferi*. *Antimicrob Agents Chemother*. 2005 Oct;49(10):4354-7.

ξ \* Ruzić-Sabljić E, Podreka T, Maraspin V, [Strle F](#). Susceptibility of *Borrelia afzelii* strains to antimicrobial agents. *Int J Antimicrob Agents*. 2005 Jun;25(6):474-8.

# Biologic Plausibility: Data NOT Cited by IDSA

§ “Lyme disease lacks characteristics of other infections that justify longer treatment, such as... infections caused by an intracellular pathogen”

§ IDSA Guidelines

§ ***Bb* is an intracellular pathogen**

§ Ma Y, Sturrock A, Weis JJ. Intracellular localization of *Borrelia burgdorferi* within human **ENDOTHELIAL CELLS**. *Infect Immun* 1991 Feb;59(2):671-8.

§ Dorward DW, Fischer ER, Brooks DM. Invasion and cytopathic killing of human **LYMPHOCYTES** by spirochetes causing Lyme disease. *Clin Infect Dis* 1997 Jul;25 Suppl 1:S2-8.

§ Montgomery RR, Nathanson MH, Malawista SE. The fate of *Borrelia burgdorferi*, the agent for Lyme disease, in mouse **MACROPHAGES**. Destruction, survival, recovery. *J Immunol* 1993 Feb 1;150(3):909-15.

§ Girschick HJ, Huppertz HI, Russmann H, Krenn V, Karch H. Intracellular persistence of *Borrelia burgdorferi* in human **SYNOVIAL CELLS**. *Rheumatol Int* 1996;16(3):125-32.

§ Livengood JA, Gilmore RD Jr. Invasion of human **NEURONAL** and **GLIAL CELLS** by an infectious strain of *Borrelia burgdorferi*. *Microbes Infect.* 2006 Nov-Dec;8(14-15):2832-40.

§ Miklossy J, Kasas S, Zurn AD, McCall S, Yu S, McGeer PL. Persisting atypical and cystic forms of *Borrelia burgdorferi* and local inflammation in Lyme neuroborreliosis. *J Neuroinflammation.* 2008 Sep 25;5:40. [**NEURONAL** and **GLIAL CELLS**]

§ **Klempner MS**, Noring R, Rogers RA. Invasion of human skin **FIBROBLASTS** by the Lyme disease spirochete, *Borrelia burgdorferi*. *J Infect Dis* 1993 May;167(5):1074-81.

# Biologic Plausibility: Data NOT Cited by IDSA

ξ “The ‘cystic’ forms of *B. burgdorferi* that have been seen under certain growth conditions in vitro have not been shown to have any clinical significance.”

ξ IDSA Guidelines

ξ “cystic forms of *Borrelia burgdorferi* and local neuroinflammation occur in the brain in chronic Lyme neuroborreliosis. The persistence of these more resistant spirochete forms, and their intracellular location in neurons and glial cells, may explain the long latent stage and persistence of *Borrelia* infection”

ξ Miklossy J, Kasas S, Zurn AD, McCall S, Yu S, McGeer PL. Persisting atypical and cystic forms of *Borrelia burgdorferi* and local inflammation in Lyme neuroborreliosis. *J Neuroinflammation*. 2008 Sep 25;5:40.

# Biologic Plausibility: Data NOT Cited by IDSA

## § In vitro evidence--Importance of Bb cystic forms

- § Schaller M; Neubert Ultrastructure of *Borrelia burgdorferi* after exposure to benzylpenicillin. *Infection*, 1994 22(6):401-406.
- § Bruck DK; Talbot ML; Cluss RG; Boothby JT. Ultrastructural characterization of the stages of spheroplast preparation of *Borrelia burgdorferi*. *J Microbiol. Methods*, 1995 (23):219-228.
- § Cluss RG; Goel AS; Rehm HL; Schoenecker JG; Boothby JT. Coordinate synthesis and turnover of heat shock proteins in *Borrelia burgdorferi*: degradation of DnaK during recovery from heat shock. *Infection & Immunity*, May1996;64(5):1736-43.
- § Kersten A; Poitschek C; Rauch S; Aberer E. Effects of penicillin, ceftriaxone, and doxycycline on the morphology of *Borrelia burgdorferi*. *Antimicrobial Agents & Chemotherapy* 1995;39(5):1127-33.
- § Aberer E; Koszik F; Silberer M. Why is chronic Lyme borreliosis chronic? *Clinical Infectious Diseases*, 25 (Suppl 1), 1997 S64-S70.

## § In vivo evidence--Importance of Bb cystic forms

- § Mursic VP, Wanner G, Reinhardt S, Wilske B, Busch U, Marget W. Formation and cultivation of *Borrelia burgdorferi* spheroplast-L-form variants. *Infection* 1996 Jul-Aug;24(4):335.
- § Miklossy J, Kasas S, Zurn AD, McCall S, Yu S, McGeer PL. Persisting atypical and cystic forms of *Borrelia burgdorferi* and local inflammation in Lyme neuroborreliosis. *J Neuroinflammation*. 2008 Sep 25;5:40.
- § Hulinska D; Jirous J; Valesova M; Hercogova J. Ultrastructure of *Borrelia burgdorferi* in tissues of patients with Lyme disease. *J Basic Microbiol*, 1989 29:73-83.
- § MacDonald AB. Concurrent neocortical borreliosis and Alzheimer's disease: Demonstration of a spirochetal cyst form. *Annals of the New York Academy of Sciences*, 1988 539:468-470.
- § Hulinska D; Bartak P; Hercogova J; Hancil J; Basta J; Schramlova J. Electron microscopy of Langerhans cells and *Borrelia burgdorferi* in Lyme disease patients. *Zbl Bakt* 1994;280:348-349.

# Biologic Plausibility: Data NOT Cited by IDSA

## ξ Both In Vitro and In Vivo

### ξ Reversion of *Bb* cystic form to spiral forms

ξ Younger cystic forms revert

ξ Older cystic forms may not revert

### ξ Virulence of cystic forms

- ξ Brorson O; Brorson SH. Transformation of cystic forms of *Borrelia burgdorferi* to normal mobile spirochetes. *Infection*, 1997 25:240-6.
- ξ Brorson O; Brorson. In vitro conversion of *Borrelia burgdorferi* to cystic forms in spinal fluid, and transformation to mobile spirochetes by incubation in BSK-H medium. *Infection* 1998; 26(3):144-50.
- ξ Gruntar I, Malovrh T, Murgia R, Cinco M. Conversion of *Borrelia garinii* cystic forms to motile spirochetes in vivo. *APMIS* 2001 May;109(5):383-8.
- ξ Miklossy J, Kasas S, Zurn AD, McCall S, Yu S, McGeer PL. Persisting atypical and cystic forms of *Borrelia burgdorferi* and local inflammation in Lyme neuroborreliosis. *J Neuroinflammation*. 2008 Sep 25;5:40.

# Animal Persistence Data Cited by IDSA

## ξ Mice and dogs remain culture and/or PCR positive after antibiotic therapy

ξ Malawista SE, Barthold SW, Persing DH. Fate of *Borrelia burgdorferi* DNA in tissues of infected mice after antibiotic treatment. *J Infect Dis* 1994; 170:1312–6.

ξ [Bockenstedt LK](#), Mao J, Hodzic E, Barthold SW, [Fish D](#). Detection of attenuated, non-infectious spirochetes in *Borrelia burgdorferi*-infected mice after antibiotic treatment. *J Infect Dis* 2002; 186:1430–7.

ξ Straubinger RK, Summers BA, Chang Y-F, Appel MJG. Persistence of *Borrelia burgdorferi* in experimentally infected dogs after antibiotic treatment. *J Clin Microbiol* 1997; 35:111–6.

ξ Straubinger RK, Straubinger AF, Summers BA, Jacobson RN. Status of *Borrelia burgdorferi* infection after antibiotic treatment and effects of corticosteroids: an experimental study. *J Infect Dis* 2000; 181:1069–81.

ξ “The significance of continued PCR positivity needs to be better understood...”

ξ IDSA Guidelines

# Animal Persistence Data NOT Cited by IDSA and New Data Published After Guidelines

ξ Mice, dogs & horses stay culture and/or PCR positive after antibiotics – 4 more studies

ξ “dead borrelial DNA does not persist in uninfected dogs for more than a few days”<sup>1</sup>

ξ Observable lameness despite antibiotic treatment<sup>1</sup>

ξ Bb from treated mice able to infect other mice<sup>2</sup>

ξ <sup>1</sup>Straubinger RK. PCR-Based quantification of *Borrelia burgdorferi* organisms in canine tissues over a 500-Day postinfection period. *J Clin Microbiol.* 2000 Jun;38(6):2191-9.

ξ <sup>2</sup>Hodzic E, Feng S, Holden K, Freet KJ, Barthold SW. Persistence of *Borrelia burgdorferi* following Antibiotic Treatment in Mice. *Antimicrob Agents Chemother.* 2008 May;52(5):1728-36.

ξ Straubinger RK, Straubinger AF, Summers BA, Jacobson RH, Erb HN. Clinical manifestations, pathogenesis, and effect of antibiotic treatment on Lyme borreliosis in dogs. *Wien Klin Wochenschr* 1998 Dec 23;110(24):874-81.

ξ Chang YF, Ku YW, Chang CF, Chang CD, McDonough SP, Divers T, Pough M, Torres A. Antibiotic treatment of experimentally *Borrelia burgdorferi*-infected ponies. *Vet Microbiol.* 2005 May 20;107(3-4):285-94.

# Lyme Disease Histology: Disease, but No Inflammation

## § Bb infection – Anti-inflammatory effects

- § Benhnia MR, Wroblewski D, Akhtar MN, Patel RA, Lavezzi W, Gangloff SC, Goyert SM, Caimano MJ, Radolf JD, Sellati TJ. Signaling through CD14 attenuates the inflammatory response to *Borrelia burgdorferi*, the agent of Lyme disease. *J Immunol*. 2005 Feb 1;174(3):1539-48.
- § Dennis VA, Jefferson A, Singh SR, Ganapamo F, Philipp MT. Interleukin-10 anti-inflammatory response to *Borrelia burgdorferi*, the agent of Lyme disease: a possible role for suppressors of cytokine signaling 1 and 3. *Infect Immun*. 2006 Oct;74(10):5780-91.
- § Lazarus JJ, Kay MA, McCarter AL, Wooten RM. Viable *Borrelia burgdorferi* enhances interleukin-10 production and suppresses activation of murine macrophages. *Infect Immun*. 2008 Mar;76(3):1153-62.

## § Human Lyme disease histology – Lack of inflammation

- § Aberer E, Kersten A, Klade H, Poitschek C, Jurecka W. Heterogeneity of *Borrelia burgdorferi* in the skin. *Am J Dermatopathol*. 1996 Dec;18(6):571-9.
- § MacDonald AB. Gestational Lyme borreliosis: implications for the fetus. *Rheumatic Disease Clinics of North America* 1989;15:657-77.

# Human Studies Documenting Persistent *Bb* Infection, Cited by The Guidelines

ξ 1148 EM patients

ξ 19 of 1148 (1.7%)-- *Bb* cultured from prior EM site

ξ Failed antibiotics described for 5 of 19 cases: ceftriaxone 14d, amoxicillin 14d, cefuroxime 14d (2), azithromycin 5d

ξ IDSA Guidelines suggest re-infection or contamination

ξ Odds of re-infection at the identical site within the few weeks between 1<sup>st</sup> & 2<sup>nd</sup> cultures would be very small

ξ *Bb* very fastidious; At time of Guidelines publication, not aware of any case of contamination ever published

ξ Hunfeld KP, Ruzic-Sabljić E, Norris DE, Kraiczy P, [Strle F](#). In vitro susceptibility testing of *Borrelia burgdorferi* sensu lato isolates cultured from patients with erythema migrans before and after antimicrobial chemotherapy. *Antimicrob Agents Chemother* 2005; 49:1294–301.

# Human Studies Documenting Persistent *Bb* Infection, but NOT Cited by The Guidelines

§ 100 culture positive EM patients

§ 58 – azithromycin 5 d, 42 – doxycycline 14 d

ξ 21% developed late Lyme, 90% subjective symptoms only

ξ Failure rate – 1.5 times higher in doxy group

§ 2 of 100 (2%) cultured *Bb* from prior EM site (1 of each group)

§ [Strle F](#), Maraspin V, Lotric-Furlan S, Ruzić-Sabljić E, Cimperman J. Azithromycin and doxycycline for treatment of Borrelia culture-positive erythema migrans. Infection. 1996 Jan-Feb;24(1):64-8.

§ 107 EM patients, 28 culture positive

§ 55 – azithromycin 5 d, 52 – doxycycline 14 d

ξ 26% developed late Lyme, 88% subjective symptoms only

ξ Failure rate – >2 times higher in doxy group

§ 5 of 28 (18%) cultured *Bb* from prior EM site (1 azithro, 4 doxy)

§ [Strle F](#), Preac-Mursic V, Cimperman J, Ruzic E, Maraspin V, Jereb M. Azithromycin versus doxycycline for treatment of erythema migrans: clinical and microbiological findings. Infection. 1993 Mar-Apr;21(2):83-8.

# Human Persistent *Bb* Infection Studies Cited by The Guidelines, but Pertinent Findings Omitted

ξ *“the detection of Osp A DNA in joint fluid indicates the presence of viable spirochetes”*

Patients	Treatment Received	SF PCR Positive After Treatment
12	< 1 month PO antibiotics	12 out of 12 (100%)
19	30-60d PO antibiotics and/or IV up to 3 wks	7 out of 19 (37%)
10	“multiple courses of antibiotic therapy”	3 out of 10 (30%)

ξ **None of the above discussed in The Guidelines**

ξ **American patients, therefore sensu stricto**

ξ Nocton J J; Dressler F; Rutledge B J; Rys P N; Persing D H; [Steere A C](#). Detection of *Borrelia burgdorferi* DNA by polymerase chain reaction in synovial fluid from patients with Lyme arthritis. N. Engl. J. Med. 1994 Jan, 330:4, 229-34.

# Human Persistent *Bb* Infection Studies Cited by The Guidelines, but Pertinent Findings Omitted

ξ 38 treated Lyme patients – Long term outcomes

ξ 26% relapsed by 1 year and required re-treatment

ξ 34% had long term morbidity despite treatment

ξ Patient #12 treated with 2 weeks IV penicillin

ξ Despite treatment, severe neurologic illness

ξ Re-treated--2 weeks IV ceftriaxone without effect

ξ She died. On autopsy, brain tissue: 2 spirochetes demonstrated with mononuclear inflammation

ξ **None of the above discussed in The Guidelines**

ξ **American patients, therefore sensu stricto**

ξ Shadick NA, Phillips CB, Logigian EL, [Steere AC](#), Kaplan RF, Berardi VP, Duray PH, Larson MG, Wright EA, Ginsburg KS, Katz JN, Liang MH. The long-term clinical outcomes of Lyme disease. A population-based retrospective cohort study. Ann Intern Med. 1994 Oct 15;121(8):560-7.

# Human Studies Documenting Persistent *Bb* Infection, but NOT Cited by The Guidelines

ξ 12 Lyme patients failed antibiotics

ξ Spirochetes in synovium: 6 of 12 patients (50%)

ξ “...the antigenic stimulus in Lyme arthritis would appear to be a small number of live spirochetes, demonstrated here by monoclonal antibodies, which may persist in the synovial lesion for years.”

ξ [Steere AC](#), Duray PH, Butcher EC. Spirochetal antigens and lymphoid cell surface markers in Lyme synovitis. Comparison with rheumatoid synovium and tonsillar lymphoid tissue. *Arthritis Rheum.* 1988 Apr;31(4):487-95.

ξ 67 yr old woman died – ARDS attributed to Lyme

ξ Failed 2 weeks tetracycline, 10 days IV penicillin, & a 2<sup>nd</sup> course IV penicillin, duration unspecified

ξ Autopsy: Lymph nodes – Spirochetes consistent with *Bb*

ξ Kirsch M, Ruben FL, [Steere AC](#), Duray PH, Norden CW, Winkelstein A. Fatal adult respiratory distress syndrome in a patient with Lyme disease. *JAMA* 1988 May 13; 259(18): 2737-9.

ξ Both studies with American patients, therefore sensu stricto

# Human Studies Documenting Persistent *Bb* Infection, but NOT Cited by The Guidelines

- ξ 15 yr old girl – Tick bite, Bell's palsy, Positive serologies
  - ξ Amoxicillin/clavulanic acid – 12 d, Doxycycline – 2 wks
  - ξ Two months later, arthritis of the knee
- ξ *Bb* culture synovial fluid: Positive – Bound mAb H5332
  - ξ Most likely sensu stricto based on monoclonal ab
- ξ Schmidli J, Hunziker T, Moesli P, Schaad UB. Cultivation of *Borrelia burgdorferi* from joint fluid three months after treatment of facial palsy due to Lyme borreliosis. *J Infect Dis* 1988 Oct; 158(4): 905-6.
- ξ 54 yr old man – 2 yrs of fevers, arthralgias, circular rashes
  - ξ Positive Lyme serologies
  - ξ After 3 wks IV penicillin, still febrile & anemic
- ξ *Bb* demonstrated in the spleen
  - ξ Cimmino MA, Azzolini A, Tobia F, Pesce CM. Spirochetes in the spleen of a patient with chronic Lyme disease. *Am J Clin Pathol* 1989 Jan;91(1):95-7.

# Human Studies Documenting Persistent *Bb* Infection, but NOT Cited by The Guidelines

- ξ 33 neuroborreliosis patients received either ceftriaxone or cefotaxime for 10 days
  - ξ At a mean of 8.1 months, 10 of 27 evaluable patients (37%) were still sick; one of them is described below:
    - ξ Persistent fevers and headaches
    - ξ Initial pleocytosis resolved after antibiotics
    - ξ Seronegative
    - ξ Normal appearing CSF without Lyme antibodies
  - ξ **Positive culture: *Bb* from normal CSF, despite prior ceftriaxone treatment**

ξ Pfister HW, Preac-Mursic V, Wilske B, Schielke E, Sorgel F, Einhaupl KMJ. Randomized comparison of ceftriaxone and cefotaxime in Lyme neuroborreliosis. *Infect. Dis.* 1991 Feb;163(2):311-8.

# Human Studies Documenting Persistent *Bb* Infection, but NOT Cited by The Guidelines

- ξ 4 Lyme arthritis patients – Initially SF PCR positive
  - ξ Failed both doxycycline 30-35 d & ceftriaxone 14-28 d
  - ξ After treatment SF PCR negative, synovial membrane PCR positive
- ξ **Re-treated longer--Oral & IV antibiotics--Arthritis resolved**
  - ξ Priem S, Burmester GR, Kamradt T, Wolbart K, Rittig MG, Krause A. Detection of *Borrelia burgdorferi* by polymerase chain reaction in synovial membrane, but not in synovial fluid from patients with persisting Lyme arthritis after antibiotic therapy. *Ann Rheum Dis.* 1998 Feb;57(2):118-21.
- ξ 68 year old woman – EM & arthralgias
  - ξ After 3 months minocycline, EM & arthralgias persisted
    - ξ Biopsy--Compatible with EM – Spirochete demonstrated
    - ξ Patient seronegative – Blood PCR positive
- ξ Minocycline for 10 months completely resolved symptoms
  - ξ **American exposure, therefore sensu stricto**
    - ξ Liegner KB, Shapiro JR, Ramsay D, Halperin AJ, Hogrefe W, Kong L. Recurrent erythema migrans despite extended antibiotic treatment with minocycline in a patient with persisting *Borrelia burgdorferi* infection. *J. Am. Acad. Dermatol.* 1993 Feb;28(2 Pt 2):312-4.

# Human Studies Documenting Persistent *Bb* Infection, but NOT Cited by The Guidelines

- ξ 42 year old man – Tick bite, EM, flu like symptoms
  - ξ Doxycycline 14 d – Transient flare of symptoms & rashes
  - ξ 4 days after stopping doxycycline, symptoms recurred
  - ξ Seronegative & no objective features described by CDC
  - ξ Chronic, severe disabling symptoms for 2 years with recurrent rashes in all the same locations
  - ξ Patient re-treated with doxycycline for 7 days
- ξ Culture of the rash resulted in *Bb* sensu lato
  - ξ Confirmed by both IFA and PCR
- ξ “Furthermore, no isolates resembling this organism are kept in our laboratory, making it impossible for the isolate to be a laboratory contaminant.”

ξ Hudson BJ, Stewart M, Lennox VA, Fukunaga M, Yabuki M, Macorison H, Kitchener-Smith J. Culture-positive Lyme borreliosis. Med J Aust. 1998 May 18;168(10):500-2.

# Human Studies Documenting Persistent *Bb* Infection, but NOT Cited by The Guidelines

- ξ 5 Lyme patients failed treatment:
  - ξ 4 of 5 – Ceftriaxone or cefotaxime for 2 weeks (1 of them also took doxycycline for 10 days)
  - ξ 1 of 5 – Doxycycline for 10 days
- ξ Cultures Positive for *Bb sensu lato*
  - ξ Skin, synovium, synovial fluid, & mitral valve:
  - ξ Confirmed by monoclonal antibodies & pulsed-field gel electrophoresis
- ξ At culture, 3 of 5 patients (60%) were seronegative & did not meet CDC case definition
- ξ Preac Mursic V, Marget W, Busch U, Pleterski Rigler D, Hagl S. Kill kinetics of *Borrelia burgdorferi* and bacterial findings in relation to the treatment of Lyme borreliosis. *Infection*. 1996 Jan-Feb;24(1):9-16.

# Human Studies Documenting Persistent *Bb* Infection, but NOT Cited by The Guidelines

- ξ 24 year old woman – EM after camping in PA
  - ξ Years later – arthritis, needed several surgeries
  - ξ Ultimately, seropositive Lyme arthritis diagnosed
  - ξ 2 courses IV penicillin, 3 of IV ceftriaxone, & 1 of IM penicillin all resulted in “dramatic reduction” of arthritis, but relapses after discontinuation of each
  - ξ Doxycycline for 13 months, sulfasalazine for 1 year, & arthroscopic synovectomy did not help
- ξ Despite multiple antibiotic treatments, synovial tissue & synovial fluid silver stain revealed copious spirochetes; synovial fluid Lyme PCR positive
- ξ **American patient, therefore sensu stricto**

ξ Battafarano DF, Combs JA, Enzenauer RJ, Fitzpatrick JE. Chronic septic arthritis caused by *Borrelia burgdorferi*. Clin Orthop 1993 Dec(297): 238-41.

# Human Studies Documenting Persistent *Bb* Infection, but NOT Cited by The Guidelines

ξ 7 Lyme patients with neurologic & urologic findings

ξ All treated with ceftriaxone, 3 wk mean

ξ 4 of 7 patients (57%) relapsed despite treatment

ξ Relapsers re-treated with ceftriaxone for 2-3 wks

ξ Antibiotics helpful in all, but 5 of 7 patients (71%) remained symptomatic

ξ Patient #2, despite 3 weeks ceftriaxone:  
Relapsed – *Bb* demonstrated in bladder biopsy,  
confirmed with monoclonal antibodies

ξ **American patient, therefore sensu stricto**

ξ Chancellor MB, McGinnis DE, Shenot PJ, Kiilholma P, Hirsch IH. Urinary dysfunction in Lyme disease. J Urol. 1993 Jan;149(1):26-30.

# Human Studies Documenting Persistent *Bb* Infection, but NOT Cited by The Guidelines

- ξ 58 year old woman, no history of tick bite or EM; neurologic manifestations
  - ξ Seronegative, CSF Lyme antibody negative
  - ξ CSF intermittently positive for *Bb* immune complexes, Osp A free antigen, and PCR
  - ξ 3 out of 7 LP's, (43%) were negative by CSF PCR
  - ξ Patient treated anyway and improved from treatment
  - ξ 7 rounds of IV antibiotics & 3 years continuous oral
  - ξ Severe Herxheimer reactions upon re-initiation of each antibiotic therapy, followed by improvements

ξ Lawrence C, Lipton RB, Lowy FD, Coyle PK. Seronegative chronic relapsing neuroborreliosis. Eur. Neurol. 1995;35(2):113-7.

# Human Studies Documenting Persistent *Bb* Infection, but NOT Cited by The Guidelines

- ξ 3 CNS Lyme patients – brain biopsy proven persistent infection after antibiotics
- ξ Patient #1
  - ξ Seronegative, CSF antibody negative, no pleocytosis
  - ξ CSF cultured positive for *Bb* sensu lato
- ξ Treated with 3 wks ceftriaxone, partial improvement
- ξ Treated with 8 months doxy, patient relapsed, Lyme PCR positive in both plasma & bone marrow
- ξ Ceftriaxone re-started, but patient died. On autopsy, brain tissue was Lyme PCR positive

ξ Oksi J, Kalimo H, Marttila RJ, Marjamaki M, Sonninen P, Nikoskelainen J, Viljanen MK. Inflammatory brain changes in Lyme borreliosis. A report on three patients and review of literature. Brain 1996 Dec; 119 ( Pt 6): 2143-54.

# Human Studies Documenting Persistent *Bb* Infection, but NOT Cited by The Guidelines

## ξ Patient #2

- ξ Initially IgM seropositive, IgG seronegative, then both seronegative despite disease progression
- ξ CSF repeatedly negative for Lyme antibodies & PCR
- ξ Brain biopsy PCR positive in 3 separate samples
  
- ξ Failure of 7 weeks ceftriaxone & almost 9 months various, often high dose oral antibiotics
- ξ After stopping antibiotics, multiple relapses with recurrent brain lesions & a positive plasma Lyme PCR
  
- ξ After another 100 days ceftriaxone, all brain lesions resolved. Patient remained well. MRI and PCR negative on long term follow up.
  
- ξ Oksi J, Kalimo H, Marttila RJ, Marjamaki M, Sonninen P, Nikoskelainen J, Viljanen MK. Inflammatory brain changes in Lyme borreliosis. A report on three patients and review of literature. *Brain* 1996 Dec; 119 ( Pt 6): 2143-54.

# Human Studies Documenting Persistent *Bb* Infection, but NOT Cited by The Guidelines

- ξ 48 year old woman with choroiditis 2 months after a tick bite & rash – Lyme serologies initially positive
  - ξ After 6 weeks doxycycline the choroiditis resolved
- ξ “The IgG titer rapidly decreased within a few weeks after the first antibiotic therapy, and remained negative in both the IF and ELISA evaluations, despite progression of the disease.”
- ξ 4 weeks post-antibiotics, arthritis in hands & EKG with newly inverted P-waves
  - ξ CSF – Negative for pleocytosis, protein, or Lyme antibody
- ξ Ceftriaxone for 2 weeks – Resolution of arthritis and rhythm disturbance
- ξ Haupt T, Hahn G, Rittig M, Krause A, Schoerner C, Schonherr U, Kalden JR, Burmester GR. Persistence of *Borrelia burgdorferi* in ligamentous tissue from a patient with chronic Lyme borreliosis. *Arthritis Rheum* 1993 Nov; 36(11): 1621-6.

# Human Studies Documenting Persistent *Bb* Infection, but NOT Cited by The Guidelines

- ξ 2 months post-ceftriaxone, choroiditis returned
  - ξ Treated – Roxithromycin & TMP/SMX
  - ξ Upon starting antibiotics, severe exacerbation of hand pain
- ξ Biopsy of flexor retinaculum – “The ligament tissue was found to be heavily infiltrated by spirochetes.”
- ξ Positive culture for *B. burgdorferi sensu stricto*
  - ξ PCR positive, amplified product hybridized using Southern blot
  - ξ Both negative and positive controls were appropriately used throughout the procedure
- ξ Haupl T, Hahn G, Rittig M, Krause A, Schoerner C, Schonherr U, Kalden JR, Burmester GR. Persistence of *Borrelia burgdorferi* in ligamentous tissue from a patient with chronic Lyme borreliosis. *Arthritis Rheum* 1993 Nov; 36(11): 1621-6.

# Human Studies Documenting Persistent *Bb* Infection, but NOT Cited by The Guidelines

- ξ 165 patients, all initially met CDC case definition
  - ξ Antibiotics – Median duration of 16 weeks
- ξ Despite antibiotics 32 of 165 (19%) relapsed
  - ξ 13 of 32 (41%) positive by culture, PCR, or both; 85% having received ceftriaxone as well as oral antibiotics
    - ξ 3 patients were culture positive
    - ξ All 13 patients re-treated– After at least 4 to 6 weeks IV ceftriaxone, 69% improved.
- ξ **One of the 3 cultures was *Bb sensu stricto***
- ξ Oksi J, Marjamaki M, Nikoskelainen J, et al. *Borrelia burgdorferi* detected by culture and PCR in clinical relapse of disseminated Lyme borreliosis. *Ann Med.* 1999 Jun;31(3):225-232.

# Human Studies Documenting Persistent *Bb* Infection, but NOT Cited by The Guidelines

- ξ Pre-antibiotics, 12 of 13 eventual relapsers (92%) were initially seropositive
- ξ Post-antibiotics, during relapse with PCR and/or culture confirmed persistent infection, only 6 of 12 relapsers (50%) IgG seropositive
  - ξ **Persistent infection despite diminishing serologies**
- ξ Immediately post-antibiotics but before clinical relapse, only 1 of 13 eventual relapsers (8%) was PCR positive
- ξ During clinical relapse, 12 of 13 patients (92%) were PCR positive
  - ξ **Increased PCR over time consistent with replication**
- ξ Oksi J, Marjamaki M, Nikoskelainen J, et al. *Borrelia burgdorferi* detected by culture and PCR in clinical relapse of disseminated Lyme borreliosis. *Ann Med.* 1999 Jun;31(3):225-232.

# Human Persistence Data NOT Cited by IDSA & New Data Published After IDSA Guidelines

## Persistent *Bb* infection despite:

- ξ Single rounds of recommended antibiotic therapy;
- ξ Multiple rounds of recommended antibiotic therapy; and
- ξ Aggressive, ie, more than 3 months of antibiotic therapy

## ξ Confirmed by culture, and/or PCR & Immuno-electron microscopy

- ξ Pícha D, Moravcová L, Holecková D, Zd'árský E, Valesová M, Maresová V, Hercogová J, Vanousová D. Examination of specific DNA by PCR in patients with different forms of Lyme borreliosis. *Int J Dermatol*. 2008 Oct;47(10):1004-10.
- ξ Hulinska D, Votypka J, Valesova M. Persistence of *Borrelia garinii* and *Borrelia afzelii* in patients with Lyme arthritis. *Zentralbl Bakteriol* 1999 Jul;289(3):301-18.
- ξ Svecová D, Gavornik P. Recurrent erythema migrans as a persistent infection. *Epidemiol Mikrobiol Imunol*. 2008 Aug;57(3):97-100.
- ξ Hulinska D, Krausova M, Janovska D, Rohacova H, Hancil J, Mailer H. Electron microscopy and the polymerase chain reaction of spirochetes from the blood of patients with Lyme disease. *Cent Eur J Public Health* 1993 Dec; 1(2): 81-5.
- ξ Aberer E, Breier F, Schmidt B. Success and failure in the treatment of acrodermatitis chronica atrophicans. *Infection* 1996;24:85-7.
- ξ Maraspin V, Ruzic-Sabljić E, **Strle F**, et al. Persistence of *Borrelia burgdorferi* after treatment with antibiotics. *Alpe Adria Microbiol J* 1995;3:211-6.

# Early Lyme: Objective vs. Subjective

ξ 74 patients with EM

Objective Findings	Subjective Symptoms
EM as Entry Criteria	Fatigue 56.8%
No A-V Block	Myalgias 43.2%
No Meningitis	Headache 39.2%
No Cranial Neuritis	Chills 35.1%
No encephalomyelitis	Joint pain 35.1%
Joint swelling in only 10.8%	(without swelling)

ξ Trevejo RT, [Krause PJ](#), Sikand VK, Schriefer ME, Ryan R, Lepore T, Porter W, Dennis DT. Evaluation of two-test serodiagnostic method for early Lyme disease in clinical practice. . J Infect Dis. 1999 Apr;179(4):931-8 .

ξ **69%\* of cases reported to CDC 1992-2006 had history of EM**

ξ Bacon RM, Kugeler KJ, Mead PS; Centers for Disease Control and Prevention (CDC). Surveillance for Lyme disease--United States, 1992-2006. MMWR Surveill Summ. 2008 Oct 3;57(10):1-9.

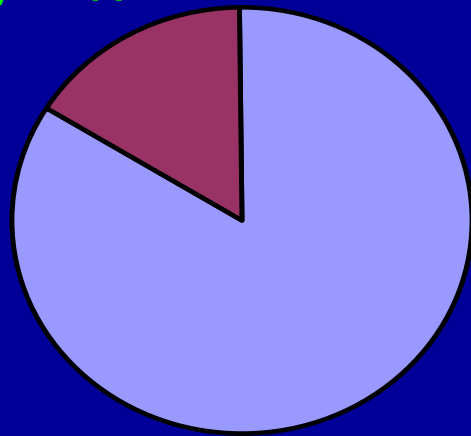
ξ **\* Skewing up is expected since EM is part of reporting criteria**

# Lyme with Only Subjective Symptoms

## Lyme Vaccine Study

### NO OBJECTIVE FEATURES

28, 16%



147, 84%

- Definite with Objective
- Definite with ONLY Subjective

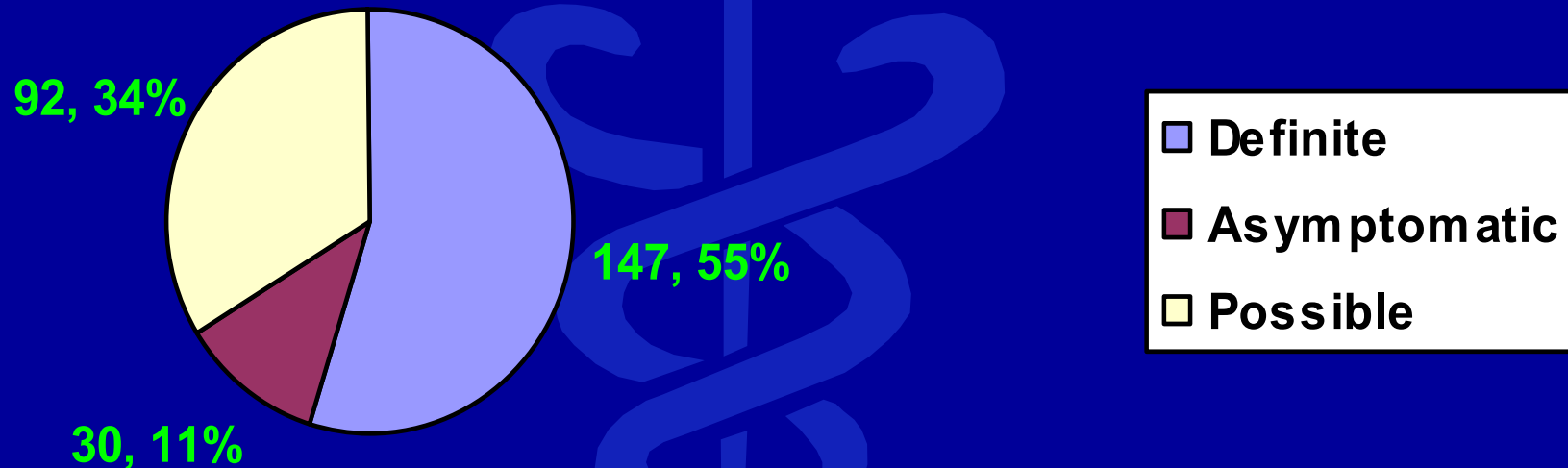
§ **Steere AC**, Sikand VK, Meurice F, Parenti DL, Fikrig E, Schoen RT, Nowakowski J, Schmid CH, Laukamp S, Buscarino C, Krause DS. Vaccination against Lyme disease with recombinant *Borrelia burgdorferi* outer-surface lipoprotein A with adjuvant. *N Engl J Med*. 1998 Jul 23;339(4):209-15.

§ **Steere AC**, Dhar A, Hernandez J, Fischer PA, Sikand VK, Schoen RT, Nowakowski J, McHugh G, Persing DH and the Lyme disease vaccine study group. Systemic symptoms without erythema migrans as the presenting picture of early Lyme disease. *Am J Med*. 2003 Jan;114(1):58-62.

# Asymptomatic Lyme Disease

Lyme Vaccine Study – 30 of 269 cases

New seroconversion by IgG Western blot



§ **Asymptomatic Lyme disease proven – So notion that Lyme disease cannot occur without objective features is untenable**

§ **Steere AC**, Sikand VK, Meurice F, Parenti DL, Fikrig E, Schoen RT, Nowakowski J, Schmid CH, Laukamp S, Buscarino C, Krause DS. Vaccination against Lyme disease with recombinant *Borrelia burgdorferi* outer-surface lipoprotein A with adjuvant. *N Engl J Med.* 1998 Jul 23;339(4):209-15.

# Human Persistent *Bb* Infection, NOT Cited by The Guidelines—Objective vs. Subjective

ξ 18 late Lyme disease patients – Failed IV antibiotics, sometimes repeatedly

ξ Despite antibiotics, all patients demonstrated:

ξ Positive *Bb* PCR and/or immuno-electron microscopy

ξ Initial testing: 7 of 18 patients (39%) seronegative

ξ Repeat testing: 12 of 18 patients (67%) seronegative

ξ 9 of 18 (50%): Non-specific symptoms at any point

ξ 12 of 18 (67%): Non-specific symptoms in later stages

ξ Honegr K, Hulínská D, Beran J, Dostál V, Havlasová J, Cermáková Z. Department of Infectious diseases, University Hospital, Hradec Králové, Long term and repeated electron microscopy and PCR detection of *Borrelia burgdorferi* sensu lato after an antibiotic treatment. Cent Eur J Public Health. 2004 Mar;12(1):6-11.

# Human Persistent *Bb* Infection, NOT Cited by The Guidelines—Objective vs. Subjective

- ξ 8 patients--originally met CDC case definition
  - ξ Myalgia despite treatment in all, 75% met American College of Rheumatology criteria for fibromyalgia
  - ξ Treated patients: : 43%--muscle biopsy Lyme PCR positive
    - ξ Most had received repeated courses of oral antibiotics & 1 course of ceftriaxone
    - ξ All were seronegative by CDC 2-tiered evaluation.
- ξ PCR methods-3 different labs, none contained previous *Bb*
- ξ All 14 negative controls remained negative
- ξ **Underscores the need for caution in diagnosing “Not-Lyme, but fibromyalgia”**
- ξ Frey M, Jaulhac B, Piemont Y, Marcellin L, Boohs PM, Vautravers P, Jesel M, Kuntz JL, Monteil H, Sibilia J. Detection of *Borrelia burgdorferi* DNA in muscle of patients with chronic myalgia related to Lyme disease. *Am J Med* 1998 Jun;104(6):591-4.

# Antibiotic Re-Treatment of Chronic Lyme Patients: Studies Demonstrating Benefits

## ξ Randomized Controlled Trials

- ξ Krupp LB, Hyman LG, Grimson R, Coyle PK, Melville P, Ahn S, [Dattwyler R](#), Chandler B. Study and treatment of post Lyme disease (STOP-LD): a randomized double masked clinical trial. *Neurology*. 2003 Jun 24;60(12):1923-30.
- ξ Fallon BA, Keilp JG, Corbera KM, Petkova E, Britton CB, Dwyer E, Slavov I, Cheng J, Dobkin J, Nelson DR, Sackeim HA. A randomized, placebo-controlled trial of repeated IV antibiotic therapy for Lyme encephalopathy. *Neurology*. 2008 Mar 25;70(13):992-1003.

## ξ Open Label Trials

- ξ Donta ST. Macrolide therapy of chronic Lyme disease. *Med Sci Monit* 2003; 9:PI136-42.
- ξ Donta ST. Tetracycline therapy for chronic Lyme disease. *Clin Infect Dis* 1997 Jul;25 Suppl 1:S52-6.
- ξ Clarissou J, Song A, Bernede C, Guillemot D, Dinh A, Ader F, Perronne C, Salomon J. Efficacy of a long-term antibiotic treatment in patients with a chronic Tick Associated Poly-organic Syndrome (TAPOS). *Med Mal Infect*. 2009 Feb;39(2):108-15.

# IDSA Guidelines – Proposed Recommendation

§ There is convincing biologic evidence for the existence of symptomatic chronic *B. burgdorferi* infection among patients after the receipt of recommended antibiotic treatment regimens for Lyme disease. Antibiotic re-treatment has proven to be beneficial in some studies, (A-I) but the best antibiotic regimens have not been established for this manifestation of Lyme disease. Prolonged oral antibiotic therapy can be beneficial for Lyme disease patients with persistent subjective symptoms and/or objective signs. (A-II). Intravenous antibiotic therapy has been studied in RCTs; it carries more risks than oral antibiotic therapy; and longer term intravenous antibiotic therapy carries greater risks than shorter term therapy. Physicians should discuss with their patients the risks and benefits of treatment options as well as the risks of withholding antibiotic treatment. Clinical judgment must be the primary basis for these decisions, which should be made on a case by case basis.



**For More Information Visit**

**ILADS.ORG**



**ILADS**